

## Foodborne parasitic infections

# CYSTIC and ALVEOLAR ECHINOCOCCOSIS



### Introduction

Human echinococcosis is a zoonotic disease caused by parasites of the genus *Echinococcus*.

Of the several species worldwide, the two most important in humans

are *E. granulosus* causing cystic echinococcosis [CE] (hydatidosis) and *E. multilocularis* causing alveolar echinococcosis [AE].

Not all genotypes of *E. granulosus* cause infections in humans.

The genotype causing the majority of CE in humans is *E. granulosus*, often maintained in a dog–sheep–dog cycle.

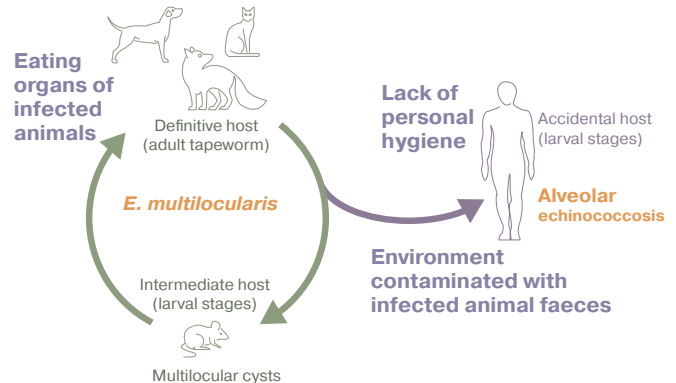
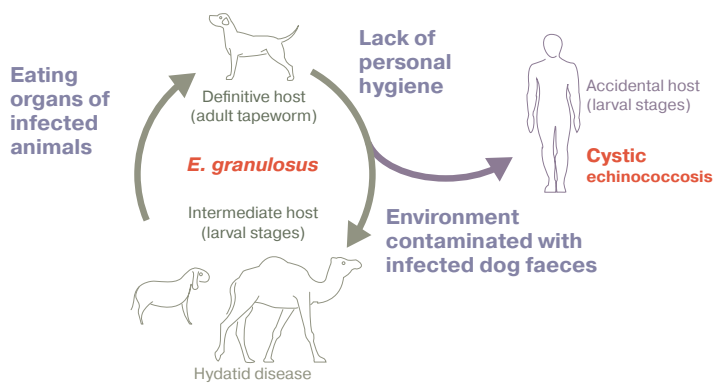


### Transmission and risk factors

Various mammals such as **sheep, goats and camels** act as intermediate hosts for CE (in which the larval stages of the worm develop), and rodents for AE. They become infected **when they ingest tapeworm eggs in contaminated soil, food or water** and the parasite develops into larval stages in their organs.

Dogs and wild carnivores act as the definitive host (in which the adult worm lives). They become infected when **they consume the organs of infected intermediate hosts that contain larval cysts**. In dogs and other carnivores, the larvae develop into adult tapeworms. They shed tapeworm eggs in their faeces and contaminate soil, food and water.

**Humans become infected through the ingestion of soil, water or food** (e.g. green vegetables, berries) contaminated with the parasites' eggs shed in the faeces of the carnivores, and also by hand-to-mouth transfer of eggs after contact with the contaminated fur of a carnivore, most commonly a dog.



### Signs and symptoms

**Cystic echinococcosis (hydatidosis):** Human infection leads to development of one or more hydatid cysts, most commonly in the liver and/or lungs. The asymptomatic incubation period of the disease can last many years until the cysts grow large enough to trigger clinical signs.

Clinical signs of cysts in the liver include abdominal pain, nausea, and vomiting. Clinical signs of cysts in the lungs include chronic cough, chest pain and shortness of breath.

**Alveolar echinococcosis:** An asymptomatic incubation period can last 5–15 years, with slow, progressive, development of a primary tumor-like lesion in the liver. Clinical signs include weight loss, abdominal pain, general malaise and hepatic failure. Metastases may spread to organs adjacent to the liver and other sites. If untreated, AE is fatal.

Animals usually do not present clinical signs for CE or AE.



### Treatment

Both AE and CE are expensive and complicated to treat. Three options for the treatment cycle of CE are: (i) percutaneous treatment of hydatid cysts with the PAIR technique, (ii) surgery, (iii) anti-infective drug treatment and (iv) “watch and wait” (active monitoring).

Treatment of AE includes radical surgery, followed by treatment with albendazole or no surgery and lifetime treatment with albendazole.

Dogs can be treated with praziquantel.



### Public health prevention and control

#### 1. Prevention and control of CE in animals

- Avoid feeding dogs with offal; safe disposal of infected offal
- Treatment of dogs with praziquantel
- Meat inspection
- Vaccination of livestock (EG95 vaccine)

#### 2. Water, sanitation and hygiene (WASH)

- Clean community water supply
- Good personal hygiene following contact with dogs

#### 3. Risk communication

Promote safe handling and disposal of offal, and personal hygiene



### Detection and diagnosis

In humans, ultrasonography, validated by CT and/or MRI scans can diagnose both CE and AE cystic lesions. Biopsies may be helpful to differentiate cysts from tumors and abscesses. Detection of specific antibodies can also support diagnosis.

In sheep, diagnosis is made at slaughter. In dogs, can be done by purging, necropsy or copro-Ag.